



Managing Incidental Findings on Abdominal CT: White Paper of the ACR Incidental Findings Committee

Lincoln L. Berland, MD^a, Stuart G. Silverman, MD^b, Richard M. Gore, MD^c, William W. Mayo-Smith, MD^d, Alec J. Megibow, MD, MPH^e, Judy Yee, MD^f, James A. Brink, MD^g, Mark E. Baker, MD^h, Michael P. Federle, MDⁱ, W. Dennis Foley, MD^j, Isaac R. Francis, MD^k, Brian R. Herts, MD^h, Gary M. Israel, MD^g, Glenn Krinsky, MD^l, Joel F. Platt, MD^k, William P. Shuman, MD^m, Andrew J. Taylor, MDⁿ

As multidetector CT has come to play a more central role in medical care and as CT image quality has improved, there has been an increase in the frequency of detecting “incidental findings,” defined as findings that are unrelated to the clinical indication for the imaging examination performed. These “incidentalomas,” as they are also called, often confound physicians and patients with how to manage them. Although it is known that most incidental findings are likely benign and often have little or no clinical significance, the inclination to evaluate them is often driven by physician and patient unwillingness to accept uncertainty, even given the rare possibility of an important diagnosis. The evaluation and surveillance of incidental findings have also been cited as among the causes for the increased utilization of cross-sectional imaging. Indeed, incidental findings may be serious, and hence, when and how to evaluate them are unclear. The workup of incidentalomas has varied widely by physician and region, and some standardization is desirable in light of the current need to limit costs and reduce risk to patients. Subjecting a patient with an incidentaloma to unnecessary testing and treatment can result in a potentially injurious and expensive cascade of tests and procedures. With the participation of other radiologic organizations listed herein, the ACR formed the Incidental Findings Committee to derive a practical and medically appropriate approach to managing incidental findings on CT scans of the abdomen and pelvis. The committee has used a consensus method based on repeated reviews and revisions of this document and a collective review and interpretation of relevant literature. This white paper provides guidance developed by this committee for addressing incidental findings in the kidneys, liver, adrenal glands, and pancreas.

Key Words: Incidental findings, incidentaloma, pancreatic cyst, renal cyst, liver lesion, adrenal nodule

J Am Coll Radiol 2010;7:754-773. Copyright © 2010 American College of Radiology

FOREWORD

This white paper is meant not to comprehensively review the interpretation and management of solid masses in each

organ system but to provide general guidance for managing incidentally discovered masses, appreciating that individual care will vary depending on each patient's specific circumstances; the clinical environment, available resources; and the judgment of the practitioner. Also, the term *guidelines* has not

^aDepartment of Radiology, University of Alabama at Birmingham, Birmingham, Alabama.

^bDepartment of Radiology, Brigham and Women's Hospital, Boston, Massachusetts.

^cDepartment of Radiology, Evanston Hospital, Evanston, Illinois.

^dDepartment of Radiology, Brown University School of Medicine, Providence, Rhode Island.

^eDepartment of Radiology, NYU-Langone Medical Center, New York, New York.

^fDepartment of Radiology, University of California, San Francisco, San Francisco, California.

^gDepartment of Diagnostic Radiology, Yale University School of Medicine, New Haven, Connecticut.

^hDepartment of Radiology, Cleveland Clinic, Cleveland, Ohio.

ⁱDepartment of Radiology, Stanford University Medical Center, Stanford, California.

^jDepartment of Radiology, Medical College of Wisconsin, Milwaukee, Wisconsin.

^kDepartment of Radiology, University of Michigan, Ann Arbor, Michigan.

^lRadiology Associates of Ridgewood, PA, Waldwick, New Jersey.

^mDepartment of Radiology, University of Washington School of Medicine, Seattle, Washington.

ⁿDepartment of Radiology, Virginia Commonwealth University Medical Center, Richmond, Virginia.

Corresponding author and reprints: Lincoln L. Berland, MD, University of Alabama at Birmingham, Department of Radiology, 619 S 19th Street, N348, Birmingham, AL 35249-1900; e-mail: lberland@gmail.com.

been used in this white paper to avoid the implication that this represents a component of the ACR Practice Guidelines and Technical Standards (which represent official ACR policy, having undergone a rigorous drafting and review process culminating in approval by the ACR Council), or the ACR Appropriateness Criteria[®] (which use a formal consensus-building approach using a modified Delphi technique). This white paper, which represents the collective experience of the Incidental Findings Committee, using a less formal process of repeated reviews and revisions of the draft document, does not represent official ACR policy. For these reasons, this white paper should not be used to establish the legal standard of care in any particular situation.

INTRODUCTION

The rapid increase in the utilization of cross-sectional imaging examinations over the past two decades, combined with the ongoing improvement in the spatial and contrast resolution of these studies, has led to a marked increase in the number of findings detected that are unrelated to the primary objectives of the examinations [1-4]. An incidental finding, also known as an incidentaloma, may be defined as “an incidentally discovered mass or lesion, detected by CT, MRI, or other imaging modality performed for an unrelated reason” [5]. Although such findings are incidental to the primary purpose of the study, one analysis suggested, “Some research and clinical activities are so prone to generating findings not intentionally sought that it is disingenuous to term them ‘unanticipated’ even if their precise nature cannot be anticipated in advance” [6]. More important than the definition is the action that each such finding invokes. So, we are asked to consider, “What is the responsible use of information that nobody asked for?” [7].

The burden of extra costs with incidental findings on cross-sectional imaging has also raised concerns within the government and third-party payers as medical imaging utilization and expenditures have risen. A recent example of this was seen in the May 2009 CMS noncoverage decision regarding screening CT colonography [8]. Although CT colonography focuses on detecting colorectal polyps to prevent colorectal carcinoma, an unenhanced, low-radiation dose CT scan of the lower chest, entire abdomen, and pelvis contains clinically significant incidental findings in 5% to 16% of asymptomatic patients [1,4,9-14], with a higher frequency in symptomatic patients [9,10,12-14]. The noncoverage decision by CMS cited concern for the costs of evaluating extracolonic findings that are diagnostically indeterminate. Other existing or developing technologies may face this type of economic scrutiny as CMS and other third-party payers become more focused on cost containment.

Although countless studies have been devoted to de-

scribing findings related to specific medical conditions, relatively little research has been devoted to understanding incidental findings. The most common reason to pursue incidental findings is to differentiate benign from potentially serious (including malignant) lesions. Although most incidental findings prove to be benign, their discovery often leads to a cascade of testing that is costly, provokes anxiety, exposes patients to radiation unnecessarily, and may even cause morbidity [15]. Articles describing criteria for detecting, categorizing, reporting, and managing such findings have been inconsistent at best and leave many unanswered questions [1,9-14].

PROJECT OBJECTIVES

The objectives of this project were:

- to develop a consensus on sets of organ-specific imaging features for some commonly affected organ systems within the abdomen, which will lead to consistent definitions for, and identification of, incidental findings;
- to develop medically appropriate approaches to managing incidental findings that are diagnostically indeterminate; and
- to address the differences between unenhanced, low-radiation dose CT examinations and contrast-enhanced CT examinations using standard radiation doses for detecting and managing incidental findings.

POTENTIAL BENEFICIAL OUTCOMES OF THE PROJECT

Benefits anticipated from this effort included:

- reducing risks to patients from additional unnecessary examinations, including the risks of radiation and risks associated with interventional procedures;
- limiting the costs of managing incidental findings to patients and the health care system;
- achieving greater consistency in recognizing, reporting, and managing incidental findings, as a component of formal quality improvement efforts;
- providing guidance to radiologists who are concerned about the risk for litigation for missing incidental findings that later prove to be clinically important; and
- helping focus research efforts to lead to an evidence-based approach to incidental findings.

HISTORY OF THE PROJECT

Because of the increasing recognition of the problems and opportunities of incidental findings, consideration of a formal approach to these issues began within the ACR in 2006. The Incidental Findings Committee was formed under the auspices of the Body Imaging Commission of the ACR. After several meetings and conference calls, the concepts and objectives described above

were formulated. The initial intent was to develop guidelines analogous to those produced by the Fleischner Society on pulmonary nodules [16] and the consensus conferences of the Society of Radiologists in Ultrasound on thyroid nodules [17] and carotid imaging [18].

Because of the keen interest among groups both within and outside the ACR, the committee's participants were recruited from members of the ACR, all of who were also fellows or members of the Society of Computed Body Tomography and Magnetic Resonance, the Society of Gastrointestinal Radiologists, and the Society of Uroradiology. Contacts from other groups within the ACR, including the Colon Cancer Committee, the Appropriateness Criteria–Adrenal Panel and the Appropriateness Criteria–GI Panel (Liver Lesion Topic) also helped ensure the consistency of the guidance produced among these groups.

CONSENSUS PROCESS

Expert radiologists in relevant organ systems were recruited to participate in the Incidental Findings Committee and its subcommittees. We plan to further review and revise these recommendations periodically, on the basis of comments and new research. Although the scope of a project to address incidental findings on CT is large, the committee decided to develop guidance for a limited number of organ systems. Four subcommittees were established to address the largest number of incidental findings within the abdomen, in the kidneys, liver, adrenal glands, and pancreas. A fifth subcommittee was charged with attempting to ensure the use of common terminology and a common format. The committee elected to defer considering other incidental findings arising in the abdomen and pelvis, such as ovarian masses, splenic lesions, lymphadenopathy, and vascular abnormalities, including arterial stenoses, abdominal aortic aneurysms, and renal artery aneurysms. The membership of each subcommittee is listed in the Appendix.

Each subcommittee was tasked to develop organ-specific guidance, which was initially formulated primarily by the subcommittee chairs. When this was complete, these subsections were distributed to the subcommittee members for further comments and discussion. Revisions of the entire document were then distributed to the subcommittee chairs, and multiple revisions ensued. Finally, the draft was distributed to the entire Incidental Findings Committee for additional review to achieve consensus and to arrive at a final manuscript. Reviews by other ACR committees were also integrated into drafts at appropriate points in the process. To facilitate rapidly formulating and clearly communicating this guidance, and to provide convenient graphic summaries for easy reference, the committee decided to express its recommendations in flowcharts and tables, buttressed with explanatory text.

ELEMENTS OF THESE RECOMMENDATIONS AND FLOWCHARTS

Certain subspecialties within radiology have addressed inconsistencies of documentation by creating structured reporting, such as the Breast Imaging Reporting and Data System[®] classification [19]. In an analogous way, Zalis et al [20], for the Working Group on Virtual Colonoscopy, proposed “C-RADS,” which includes an “E” classification system for extracolonic findings. Although this latter classification system has elements in common with these recommendations, it is not included with them here.

In the flowcharts within this white paper, the algorithms use yellow boxes for steps that involve data to affect management, such as categorization, demographics, history, and the results of studies. Green boxes represent action steps, such as performing a study, following up, or intervening with a biopsy or surgery. Red boxes indicate that the evaluation process should stop, with no further action required, because the lesion can be concluded to be benign.

CHALLENGES OF ADDRESSING INCIDENTAL FINDINGS

One of the crucial obstacles to managing incidental findings cost-effectively is the unwillingness of many physicians to accept uncertainty even when the chance of a serious diagnosis is extremely unlikely. This unwillingness is in part driven by a paucity of data, the lack of clear-cut algorithms with regard to diagnostic and treatment strategies, fear of potential malpractice litigation, and the desire of patients and their families to adhere to the adage “better safe than sorry.” It may be difficult for physicians or patients to appreciate at an intellectual or emotional level that an incidental finding might not need to undergo further examinations or follow-up. Not only are further tests likely to yield a benign diagnosis, but such testing could even lead to morbidity [15]. On the other hand, an incidental finding could represent a serendipitous discovery of a serious diagnosis, such as a large abdominal aortic aneurysm, and be potentially lifesaving; hence the conundrum. The discussion of cost is also burdened with strong opinions, with some believing that cost should be no obstacle to reaching a comfortable level of medical certainty for a positive or negative diagnosis [21,22]. Others might argue that medical resources should be best applied where they are known to be most effective. However, there is strong scientific validation for applying medical strategies that optimize results while minimizing costs and applying “evidence-based” reasoning to medical decisions [21].

Unfortunately, information about the cost-effectiveness of pursuing incidental findings is largely lacking. Therefore, achieving a consensus of experts, supported by available literature, is a reasonable interim objective

for this Incidental Findings Committee. However, there are several reasons to hypothesize that a group of specialty radiologists from academic institutions might be biased toward the overuse of imaging studies. For example, the culture of attempting to achieve diagnostic certainty noted above may be more intense in an academic environment, partly because of the higher intensity of illness seen there. Less experienced physicians in residency and fellowship may be more inclined to depend on imaging studies, with this inclination supported by attending physicians wanting to enhance the teaching experience. Also, academic institutions are more likely to have a broad array of advanced imaging technologies, the use of which is encouraged by the desire to perform research.

Additionally, academic experts are intensely focused in their areas of interest and are keenly aware of the multitude of possible serious results from incidental findings, also potentially biasing their viewpoint. Therefore, in approaching incidental findings in this way, there is a risk that rather than the results of this project limiting the overuse of imaging, the detailed guidance generated from this project either might not affect such overutilization or could even increase it. Our goal was not necessarily to reduce utilization (although we believe this is needed) but rather to optimize utilization. In this way, only the appropriate incidental findings are evaluated further. These factors were considered in designing these recommendations, especially regarding the guidance on the length and frequency of follow-up studies for indeterminate lesions.

REPORTING CONSIDERATIONS

Some considerations are common to all organ systems. One universal principle is to refer to available prior relevant imaging examinations when interpreting incidental findings. Prior examinations need not be of precisely the same type or modality but are useful if they include the anatomic area in question, such as a chest CT scan that includes the upper abdomen. Also, the approach to incidental findings should be placed in the context of the individual patient's situation. As an extreme but common example, the need to report or pursue incidental findings may be unnecessary in patients with serious medical comorbidities or limited life expectancy.

The wording of the radiology report is also controversial and could fall into 4 categories. This can be illustrated through the example of a renal mass that seems to be a simple cyst on an unenhanced CT scan. Such a lesion could be:

1. Described as a "low-attenuation mass statistically likely to be a simple cyst" or a "low-attenuation mass likely to be benign;"
2. Reported as a "renal cyst." This contains the specific, implicit recommendation to do nothing and limits

the length of the radiology report but might be inaccurate in a small percentage of situations;

3. Not reported at all. Particularly in the case of small lesions, some would argue that such a finding is so common and innocuous that it does not rise to the level of an abnormality. Refraining from reporting would be analogous to a nonradiologist physician not mentioning an insignificant skin lesion on a physical examination report. Because many patients and some physicians become concerned about even minor findings, this would prevent any risk for further testing; or
4. Reported by stating that a definitive diagnosis cannot be made, but there are no features to suggest a malignant etiology, with one possible phrase being "indeterminate, no malignant features." This would leave the workup to the discretion of the referring physician and perhaps the patient. However, such a report leaves the referrer in a quandary. This may lead to unnecessary testing, but it would essentially acknowledge the limits of the examination and acknowledge that there are no evidence-based data to allow specific recommendations.

Option 1 was considered acceptable, but not necessarily preferred, by all members of the Incidental Findings Committee. However, the committee could not reach a consensus on all aspects of this subject, because various members preferred, while others raised objections to each of options 2, 3, and 4. Some members noted that reporting all incidental findings can be valuable if a patient has a follow-up examination and only the report is available.

SCANNING TECHNIQUES

In the 4 organ-specific sections below (kidneys, liver, adrenal glands, and pancreas), comments apply to standard-radiation dose examinations, whether performed unenhanced or enhanced. However, low-dose unenhanced scans may be performed for CT colonography, identifying urinary tract calculi and other applications. We believe that incidental findings identified on such low-radiation dose, unenhanced scans require special considerations. These are separately addressed in an additional section following the 4 organ-specific sections.

KIDNEYS

Nature and Scope of the Problem

The literature regarding the approach to renal masses detected on renal mass-protocol CT or MRI is replete with case series, retrospective analyses, and suggested clinical guidelines that have been long accepted and are widely adopted in clinical practice today [23-47]. A summary and update of these guidelines, discussed in the context of an

Table 1. Management recommendations for patients with incidental cystic renal masses

Bosniak Category	Appearance Imaging Features	Recommendation	
		General Population	Comorbidities or Limited Life Expectancy
I†	Hairline-thin wall; no septa, calcifications, or solid components; water attenuation; no enhancement	Ignore	Ignore
II	Few hairline-thin septa with or without perceived (not measurable) enhancement; fine calcification or short segment of slightly thickened calcification in the wall or septa; homogeneously high-attenuating masses (≤ 3 cm) that are sharply marginated and do not enhance	Ignore	Ignore
IIF	Multiple hairline-thin septa with or without perceived (not measurable) enhancement, minimal smooth thickening of wall or septa that may show perceived (not measurable) enhancement, calcification may be thick and nodular but no measurable enhancement present; no enhancing soft tissue components; intrarenal nonenhancing high-attenuation renal masses (> 3 cm)	Observe*§	Observe§ or ignore
III	Thickened irregular or smooth walls or septa, with measurable enhancement	Surgery‡	Surgery‡ or observe§
IV	Criteria of category III, but also containing enhancing soft tissue components adjacent to or separate from the wall or septa	Surgery‡	Surgery‡ or observe§

Note: These recommendations are to be followed only if nonneoplastic causes of a renal mass (eg, infections) have been excluded; see text for details. The recommendations are offered as general guidance and do not necessarily apply to all patients. Reprinted with permission from Radiology 2008;249:16-31.

*In selected patients (eg, young), early surgical intervention may be considered, particularly if a minimally invasive approach (eg, laparoscopic partial nephrectomy) can be used.

†When a mass < 1 cm has the appearance of a simple cyst, further workup is not likely to yield useful information.

‡Surgical options include open or laparoscopic nephrectomy and partial nephrectomy; each provides a tissue diagnosis. Open, laparoscopic, and percutaneous ablation may be considered when available, but biopsy would be needed to achieve a tissue diagnosis. Long-term (5-year or 10-year) results of ablation are not yet known.

§Computed tomography or MRI at 6 and 12 months, then yearly for 5 years; the interval and duration of observation may be varied (eg, longer intervals may be chosen if the mass is unchanged, longer duration may be chosen for greater assurance).

||Cystic masses ≤ 1.5 cm that are not clearly simple cysts or that cannot be characterized completely may not require further evaluation in patients with comorbidities and in patients with limited life expectancy. Reprinted with permission from Radiology 2008;249:16-31.

incidental finding, has been recently detailed [48] and thus is not entirely repeated in this white paper.

Detection and Characterization

A renal mass can be found incidentally, either as part of an examination that allows the mass to be fully characterized or as part of an examination that does not allow the mass to be evaluated fully. Many renal masses can be characterized completely using ultrasound or contrast material-enhanced CT; however, some renal masses may require additional imaging [23-47]. Renal mass-protocol CT or MRI examinations (scans obtained both before and after intravenous contrast material) allow

most renal masses to be fully characterized. Renal masses are divided into cystic and solid types, and recommendations are detailed for each and for both the general population and patients with comorbidities or limited life expectancy (Tables 1-3). In general, the suggested management of renal masses begins first with ensuring that the mass is not the result of a nonneoplastic condition that can mimic a tumor. These conditions include pseudotumors such as columns of Bertin, hypertrophied tissue adjacent to scars, vascular anomalies and aneurysms, infarcts, and infections. Focal bacterial pyelonephritis commonly causes a masslike abnormality in the kidney. Also, fat-containing angiomyolipomas should be

Table 2. Management recommendations for incidental solid renal masses in patients in the general population

Mass Size	Probable Diagnosis	Recommendation	Comment
Large (>3 cm)	Renal cell carcinoma†	Surgery‡	Angiomyolipoma with minimal fat, oncocytoma, other benign neoplasms may be found at surgery
Small (1-3 cm)	Renal cell carcinoma†	Surgery‡	If hyperattenuating, and homogeneously enhancing, consider MRI and percutaneous biopsy to diagnose angiomyolipoma with minimal fat
Very small (<1 cm)	Renal cell carcinoma, oncocytoma, angiomyolipoma*	Observe until 1 cm§	Thin (≤3 mm) sections help confirm enhancement

Note: These recommendations are best followed after nonneoplastic causes of a renal mass (eg, infections) have been excluded; see text for details. The recommendations are offered as general guidance and do not necessarily apply to all patients.

*Benign entities are more likely in small renal masses than large ones.

†Provided there is no detectable fat by CT or MRI using protocols designed to evaluate renal masses.

‡Surgical options include open or laparoscopic nephrectomy and partial nephrectomy; both provide a tissue diagnosis. Open, laparoscopic, and percutaneous ablation may be considered when available, but biopsy would be needed to achieve a tissue diagnosis. Long-term (5-year or 10-year) results of ablation are not yet known.

§Computed tomography or MRI at 3 to 6 months, 12 months, and then yearly; the interval and duration of observation may be varied (eg, shorter intervals if the mass is enlarging). Reprinted with permission from Radiology 2008;249:16-31.

excluded. With rare exceptions, a mass that contains fat, particularly when not calcified, can be diagnosed as an angiomyolipoma with confidence. The subsequent management then can be derived and is summarized in Tables 1 to 3. These tables are reconfigured in the form of flowchart algorithms in Figures 1 and 2.

The approach to the cystic renal mass follows the time-tested approach of Bosniak [23,25,27-32]. The tables and flowcharts are constructed so that both patients in the general population and those with limited life expectancy can be managed. In general, size is not a factor in the Bosniak classification of cystic renal masses, because large cystic masses are often benign, and small ones may be malignant. However, the smaller the mass, the more likely it is benign. Therefore, the commonly encountered cystic-appearing renal mass that is too small to evaluate all of its features, including its CT attenuation, can be presumed to be benign if it does not display any nonsimple features. In the green “action boxes” in the flowcharts (Figures 1 and 2), observation with imaging, also known as active surveillance [49,50], is recommended for indeterminate masses in Bosniak category IIF and is also an option for masses in categories III and IV in patients with limited life expectancy or comorbidities that would increase the risk of treatment.

There is no known interval of time that can be used to diagnose an indeterminate renal mass with certainty, although 5 years has been suggested as a reasonable length

of time to diagnose an indeterminate renal mass as benign on the basis of the lack of morphologic change [36,48]. Depending on the level of suspicion, and patient and referrer comfort with observation, both the duration and interval may be altered. As indicated in Tables 1 to 3 and the flowcharts (Figures 1 and 2), growth alone cannot be used to definitively diagnose a mass (whether solid or cystic) as malignant. Benign masses may grow, and malignant ones may grow little, if at all [51,52].

Regarding the flowchart for cystic renal masses (Figure 1), both Bosniak category III and IV masses are managed surgically; however, category IV masses have a greater probability of malignancy than category III masses, and management approaches other than resection carry more risk. Because many Bosniak category III masses are malignant, surgery is recommended for the general population. Percutaneous biopsy of Bosniak category III renal masses, although controversial, may be helpful, particularly in patients with comorbidities that would pose risk to patients undergoing surgery [34,46]. If a definitive malignant result can be obtained with biopsy, surgery may be planned with confidence. For a benign biopsy result to be useful, it should be both definitive and specific of a benign entity. Biopsy results that reveal nonspecific cells should be viewed with caution and cannot be used alone to guide management. Because Bosniak category III masses typically contain few solid elements, it may be difficult to both target and procure diagnostic

Table 3. Management recommendations for incidental solid renal masses in patients with limited life expectancy or comorbidities that increase the risk of treatment

Mass Size	Probable Diagnosis	Recommendation	Comment
Large (>3 cm)	Renal cell carcinoma†	Surgery‡ or observe	Angiomyolipoma with minimal fat, oncocytoma, other benign neoplasms may be found at surgery; biopsy can be used preoperatively to confirm renal cell carcinoma
Small (1-3 cm)	Renal cell carcinoma†	Surgery‡ or observe	If hyperattenuating, and homogeneously enhancing, consider MRI and percutaneous biopsy to diagnose angiomyolipoma with minimal fat
Very small (<1 cm)	Renal cell carcinoma, oncocytoma, angiomyolipoma*	Observe until 1.5 cm§	Thin (≤3 mm) sections help confirm enhancement

Note: These recommendations are best followed after nonneoplastic causes of a renal mass (eg, infections) have been excluded; see text for details. The recommendations are offered as general guidance and do not necessarily apply to all patients.

*Benign entities are more likely in small renal masses than large ones.

†Provided there is no detectable fat by CT or MRI using protocols designed to evaluate renal masses.

‡Surgical options include open or laparoscopic nephrectomy and partial nephrectomy; both provide a tissue diagnosis. Open, laparoscopic, and percutaneous ablation may be considered when available, but biopsy would be needed to achieve a tissue diagnosis. Long-term (5-year or 10-year) results of ablation are not yet known.

§Computed tomography or MRI at 3 to 6 months, 12 months, and then yearly; the interval of observation may be varied (eg, shorter intervals if the mass is enlarging); the duration of observation may be individualized. Observation may be considered for a solid renal mass of any size in a patient with limited life expectancy or comorbidities that increase the risk of treatment, particularly when the mass is small. It may be safe to observe a solid renal mass beyond 1.5 cm, but there are insufficient data to provide definitive recommendations on the risks and benefits of observation. Reprinted with permission from *Radiology* 2008;249:16-31.

tissue for biopsy, limiting the ability to achieve definitively benign or malignant results. However, even if a confident diagnosis of a benign entity can be made in these patients, observation is still warranted.

We define solid masses as those that contain little or no fluid attenuating (<20 Hounsfield units [HU]) components and usually consist predominantly of enhancing tissue (Tables 2 and 3, Figure 2). As described for cystic renal masses, all solid masses should be evaluated first for features suggesting a nonneoplastic etiology, such as focal bacterial pyelonephritis or other conditions noted above. A thorough search for fat cells using CT or MRI protocols designed to evaluate renal masses should also be undertaken. Although there are rare exceptions, fat-containing noncalcified renal masses in adults can be diagnosed as benign angiomyolipomas with confidence [48]. The subsequent approach to a solid renal mass is then predicated mostly on size. Although there is no single feature of a renal mass that can be used to predict its biologic behavior accurately, size is a reasonable and practical approach. In general, large (>3 cm) solid renal masses are likely malignant; similarly, the smaller a solid mass, the more likely it is benign. In addition, a small renal cell carcinoma is more likely to be low grade and indolent behaving than a larger one [53]. Therefore, we have sug-

gested that solid masses <1 cm be observed [48]. This approach is further supported by the difficulty of confirming that masses of this size are enhancing and are therefore solid. Partial volume effects can mimic enhancement. Thus, the use of thin-section (≤3 mm) CT and MRI is advised when both evaluating and observing such small masses. However, there are rare cases of aggressively behaving small renal cell carcinomas, even those <1 cm. Therefore, observation is not completely without risk [54].

Solid renal masses between 1 and 3 cm can be characterized as enhancing with confidence. Unlike masses <1 cm, these masses are large enough to be targeted for percutaneous biopsy. Although still somewhat controversial, in some patients, biopsy can be used to provide a definitive diagnosis of oncocytoma and angiomyolipoma, the two most common benign neoplasms found after surgical resection of a solid renal mass [53,55]. Because an angiomyolipoma with minimal fat typically presents as a hyperdense, T2-hypointense, homogeneously enhancing mass, MRI, with or without CT, can be used to identify such masses and lead to percutaneous biopsy [41,47,48]. Although oncocytomas are typically homogeneously enhancing masses and may display a central scar, these features may also be found in oncocytic renal cell carcinomas. Therefore, specific recom-

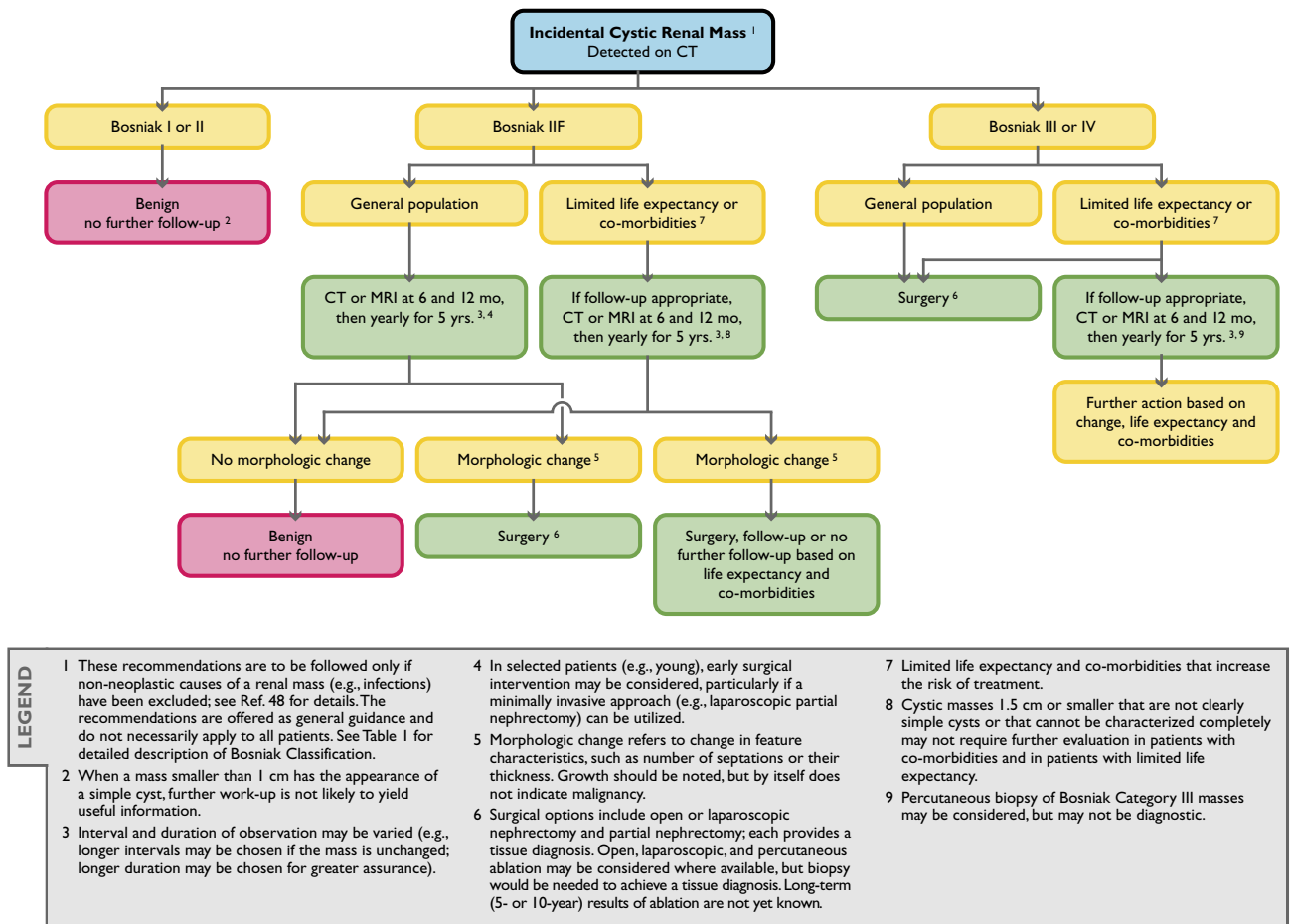


Fig 1. Flowchart for incidental cystic renal mass detected on CT.

mendations as to which masses should undergo percutaneous biopsy cannot be made.

LIVER

Nature and Scope of the Problem

Recent advances in multidetector CT, MRI, ultrasound and 2-¹⁸F-fluoro-2-deoxyglucose PET have led to the detection of incidental hepatic masses in both the oncology and nononcology patient population that in the past remained undiscovered. This has engendered a management dilemma that is particularly pertinent to oncology patients, in whom any hepatic mass, clinical or subclinical, warrants attention. At autopsy, as many as 52% of noncancer patients have benign hepatic lesions, and liver metastases are found in as many as 36% of patients dying with cancer [56]. Key questions to answer include the following: (1) Does the hepatic incidentaloma put the patient at risk for an adverse outcome? (2) Can a primary or metastatic malignancy be accurately and confidently differentiated from a benign incidentaloma? and (3) If a

benign lesion, might it still require surgical intervention, such as resecting a hepatic adenoma to prevent rupture?

Implications of Imaging and Clinical Features

Strategies for optimizing the management of these lesions are only beginning to emerge in terms of deciding which of these incidental liver masses may not need further evaluation, which may simply be monitored over time, and which require more aggressive workup. Preoperative percutaneous biopsy may minimize diagnostic error but is associated with a postprocedural morbidity of 2.0% to 4.8% and mortality of 0.05% [57-59].

The Incidental Findings Committee's guidance for managing liver incidental findings is illustrated in Figure 3. Managing incidental liver lesions depends on the probable importance of the mass. This is assessed both by the appearance of the mass and the level of risk that each patient has for developing important liver masses. Important liver masses are not limited to malignancies. For example, a benign hepatic adenoma might require surgical intervention. These categories are defined as follows:

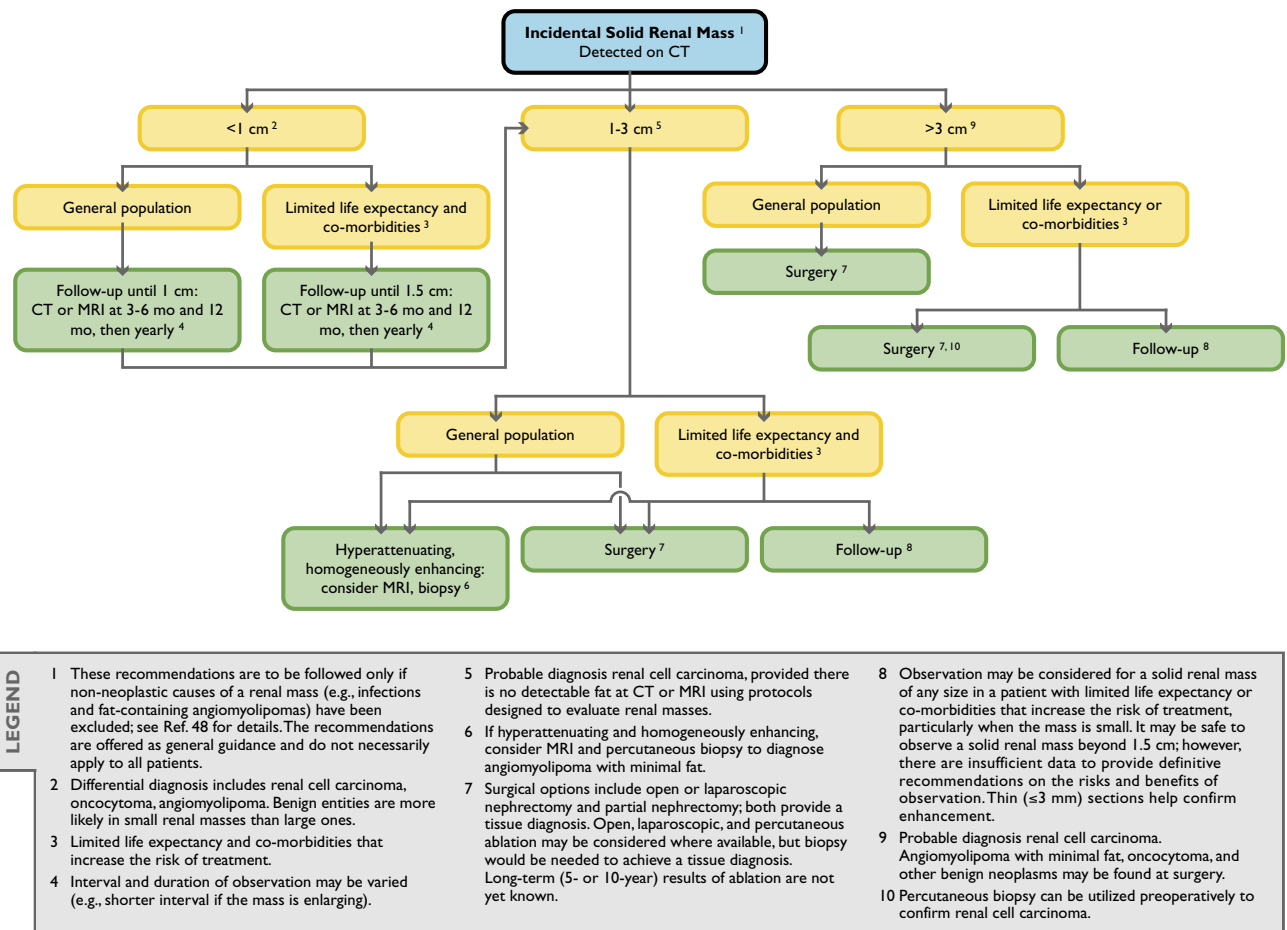


Fig 2. Flowchart for incidental solid renal mass detected on CT.

1. Low-risk individuals: Young patients (aged ≤ 40 years), with no malignancies, hepatic dysfunction, hepatic malignant risk factors, or symptoms attributable to the liver.
2. Average-risk individuals: Patients aged > 40 years, with no known malignancies, hepatic dysfunction, hepatic malignant risk factors, or symptoms attributable to the liver.
3. High-risk individuals: Patients with known primary malignancies with a propensity to metastasize to the liver, cirrhosis, or other hepatic risk factors. Hepatic risk factors include hepatitis, chronic active hepatitis, sclerosing cholangitis, primary biliary cirrhosis, hemochromatosis, hemosiderosis, hepatic dysfunction, and long-term oral contraceptive use.

ADRENAL GLANDS

Nature and Scope of the Problem

An incidental adrenal mass, often referred to as an adrenal incidentaloma, is defined as an adrenal mass (≥ 1 cm) discovered incidentally on a cross-sectional imaging examination performed for another reason. Incidental adrenal masses are very common, estimated to occur in approximately 3% to 7% of the adult population [60-

63]. The most frequent pathology for an incidentally discovered adrenal mass is a nonhyperfunctioning adenoma [64]. It was shown in one study that the overwhelming majority of incidentally discovered adrenal masses are benign in patients with no known malignancies [65]. Statistics indicate that given the high prevalence of nonhyperfunctioning adrenal adenomas in the general population, an incidentally discovered adrenal mass in an oncology patient is most likely benign. However, the adrenal gland is also a common site for metastases and, somewhat less commonly, primary adrenal tumors, including pheochromocytomas, aldosteronomas, and adrenal cortical carcinomas.

The goal of imaging when an incidental adrenal mass is discovered is to differentiate a benign “leave-alone” mass (eg, nonhyperfunctioning tumor, myelolipoma, hemorrhage, cyst) from a mass that warrants treatment (eg, metastasis, pheochromocytoma, adrenal cortical carcinoma). From an imaging perspective, an optimal algorithm should be used to diagnose both leave-alone masses and masses that need treatment, using as few tests as possible. The adrenal flowchart (Figure 4) and recommendations described here at-

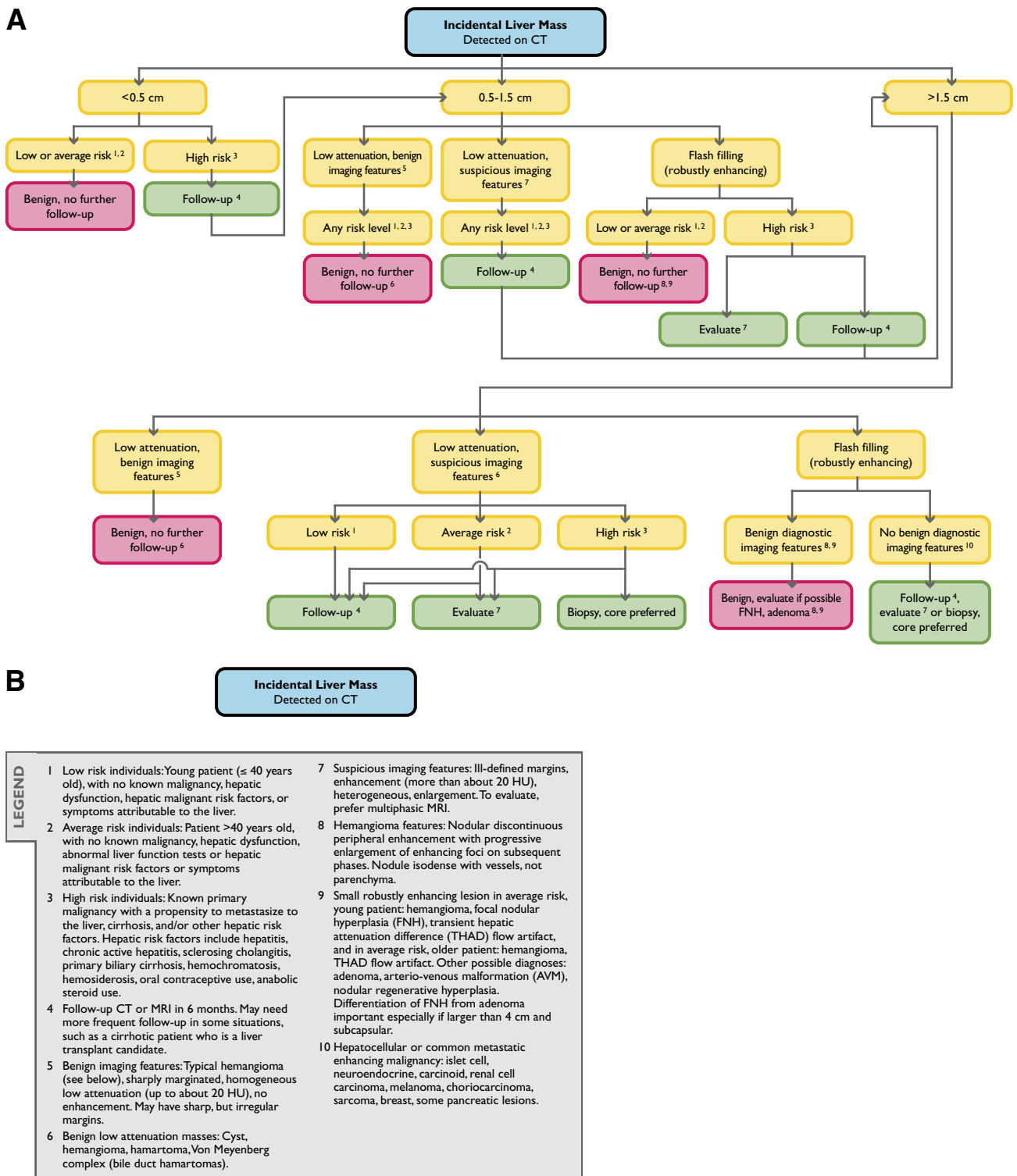


Fig 3. Flowchart for incidental liver mass detected on CT.

tempt to do both. The algorithm reflects the most commonly encountered imaging scenarios. However, it is important to note that there are exceptions to some of the recommendations depending on individual patients' presentations and histories. As noted in

other sections of this white paper, if a patient has limited life expectancy or severe comorbidities, workup of an incidentally discovered adrenal mass may not be appropriate. Readers are also directed to a recent comprehensive review on this topic [66].

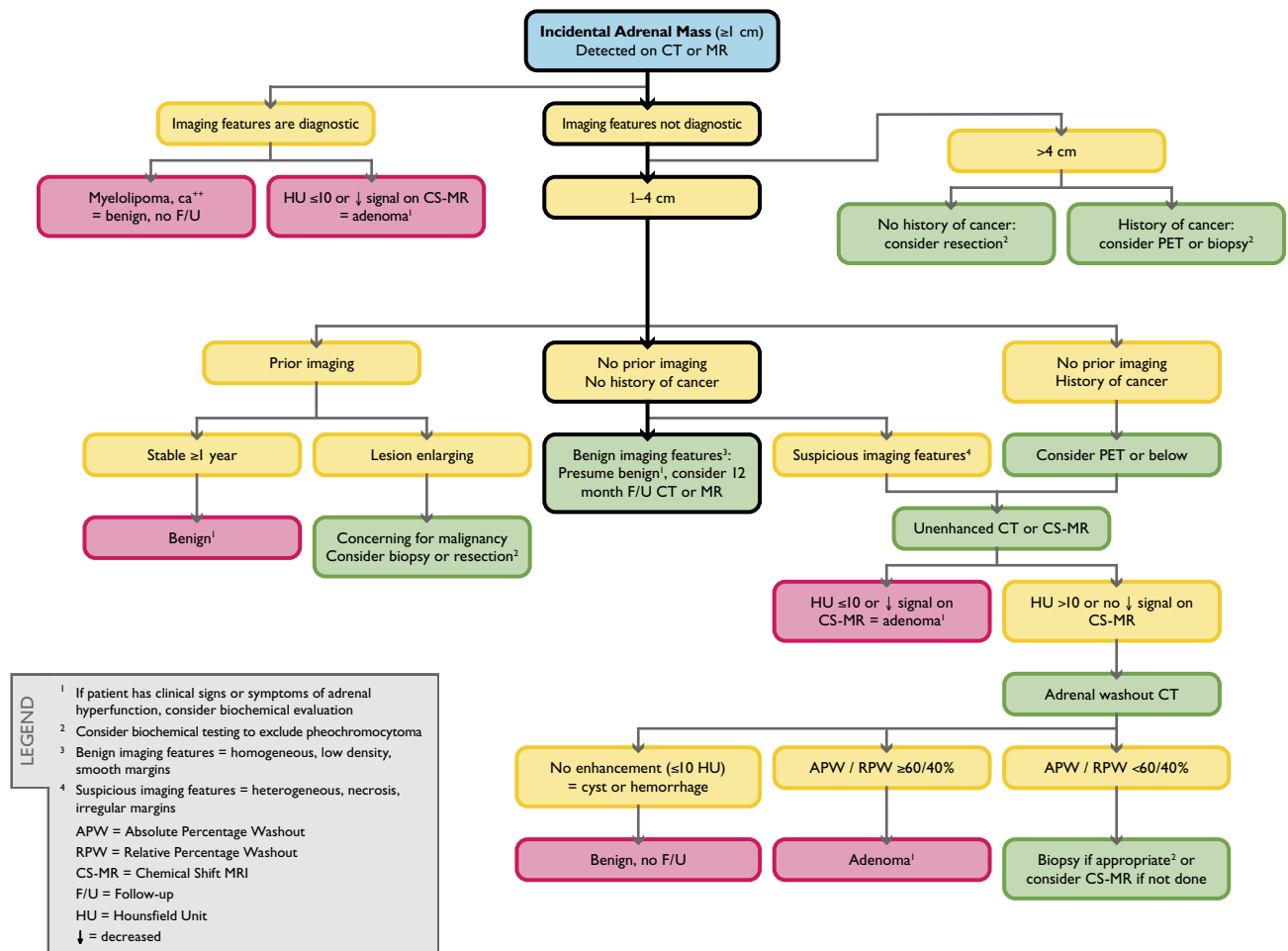


Fig 4. Flowchart for incidental adrenal mass detected on CT or MR.

Imaging Characterization and Workup Algorithm

If an adrenal mass has diagnostic features of a benign lesion such as a myelolipoma (presence of macroscopic fat) or cyst (simple cyst-appearing without enhancement), no additional workup or follow-up imaging is needed. If the lesion is 1 to 4 cm and has a density of ≤ 10 HU on CT or signal loss compared with the spleen on out-of-phase images of a chemical-shift MRI (CS-MRI) examination, it is almost always diagnostic of a lipid-rich adenoma [67-72]. If diagnostic imaging features are not present but the adrenal mass has been stable for ≥ 1 year, it is likely benign [66].

If a patient has no history of cancer, there are no prior examinations, and the mass has benign imaging features (low density, homogeneous with smooth margins), one may consider a follow-up unenhanced CT or CS-MRI examination in 12 months. However, if there are suspicious imaging features on contrast-enhanced CT, such as necrosis, heterogeneous density, or irregular margins, one could proceed with an unenhanced CT or CS-MRI

examination. If these do not confirm that the lesion is a lipid-rich adenoma, adrenal washout CT with 15-minute delayed imaging to calculate contrast material washout may be helpful [73-75].

In patients with histories of cancer and adrenal masses, if the imaging features are not diagnostic and there is no prior imaging to confirm stability, one may consider unenhanced CT, CS-MRI, or PET imaging [76]. If the mass cannot be diagnosed as a lipid-rich adenoma, adrenal washout CT may be helpful. In patients with no histories of cancer and adrenal masses > 4 cm, one may consider resection.

Adenomas typically enhance rapidly using either iodinated contrast material or gadolinium chelates and also display rapid washout [74]. Although metastases generally enhance rapidly, their washout is more prolonged. Using CT, absolute percentage washout values are calculated using the formula $(\text{enhanced HU} - 15\text{-minute delayed HU}) / (\text{enhanced HU} - \text{unenhanced HU}) \times 100$. A value of $\geq 60\%$ is diagnostic of an adenoma. Relative percentage washout is used when an un-

hanced CT value is not available and the enhanced values are compared with 15-minute delayed scans. Relative percentage washout is calculated using the formula (enhanced HU – 15-minute delayed HU)/enhanced HU × 100; a value of >40% is diagnostic for an adenoma [73-75]. Adrenal washout CT was used successfully to distinguish adenomas from nonadenomas in 160 of 166 adrenal masses with 98% sensitivity and 92% specificity [73].

Recent advances in imaging characterization with CT, MRI, and PET have decreased the need for image-guided percutaneous biopsies to characterize adrenal masses [77]. However, if an adrenal mass is enlarging, it may be prudent to proceed to percutaneous adrenal biopsy or surgical resection. In an oncology patient, a new adrenal mass in a patient with known metastases elsewhere is most likely another metastasis. However, an isolated adrenal mass could be benign or malignant. If the mass cannot be characterized as an adenoma using CT, MRI, or PET, a biopsy may be appropriate. If there are signs or symptoms of pheochromocytoma, it may be prudent to obtain plasma-fractionated metanephrine and normetanephrine levels before biopsy [78].

Imaging examinations are useful to separate adrenal adenomas from other masses but cannot be used to distinguish hyperfunctioning adenomas from nonhyperfunctioning adenomas. One approach would be to rely on history and physical examination to determine which patients should undergo biochemical testing for hyperfunctioning adrenal neoplasms. Some endocrinologists recommend excluding an occult, asymptomatic hyperfunctioning neoplasm in all adrenal incidentalomas [60,62,63]. This approach would be costly and is not routinely performed by many physicians. Regarding the radiology report, when an adenoma can be diagnosed with imaging, we suggest stating, “Findings consistent with a benign adenoma. If there are clinical signs or symptoms of adrenal hyperfunction, biochemical evaluation may be appropriate.”

PANCREAS

Nature and Scope of the Problem

The frequency of detection of pancreatic cysts by CT scanning is reported between 1.2% [79] and 2.6% [80]. For MRI, the reported frequency is significantly higher, at 19.9% of MRI examinations [81]. Because pancreatic cysts are quite prevalent, a practicing radiologist may see several for every 100 abdominal imaging cases performed.

Cystic pancreatic tumors are most often frankly benign or low-grade indolent neoplasms. In one study that included asymptomatic patients with pancreatic cysts in whom there was operative correlation, 17% of asymp-

tomatic cysts were serous cystadenomas, 28% were mucinous cystic neoplasms, 27% were intraductal papillary mucinous neoplasms (IPMNs), 2.5% were ductal adenocarcinomas, and 3.8% were pseudocysts [82]. Intraductal papillary mucinous neoplasms were the most common cystic neoplasm when both symptomatic and asymptomatic patients were evaluated. In another series, 39% of IPMNs were incidentally detected, and 50% of IPMNs were side branch or branch duct IPMNs with a 5-year risk for developing high-grade dysplasia or invasive carcinoma of 15% [83].

Mucinous cystic masses, namely IPMNs and mucinous cystic neoplasms, have a well-established malignant potential likened to an adenoma-carcinoma sequence [84]. Because of this malignant potential, it has become increasingly difficult for radiologists evaluating individual cases to know how to frame the report to help guide appropriate management. We believe that the guidance below will help in the evaluation and reporting of the majority of these lesions. These recommendations are also summarized in Figure 5.

Detection and Characterization

This discussion is limited to unexpected pancreatic cysts in asymptomatic patients. Asymptomatic patients have no clinical or laboratory indication directly referable to the pancreas, including but not limited to hyperamylasemia, recent-onset diabetes, severe epigastric pain, weight loss, or jaundice. The most frequently detected cyst is <10 mm in size [85]. Cysts of this size are particularly prevalent on MRI. Imaging will not be able to characterize these lesions. The question of appropriate follow-up is subsequently addressed.

There is ample literature to support the nonsurgical management of pancreatic cysts <3 cm that do not display “worrisome features” [86-90]. Some recommend 2.5 cm as a maximal diameter for nonsurgical management [91]. Worrisome features include larger size, presence of mural nodules, dilation of the common bile duct, involvement of the main pancreatic duct, and lymphadenopathy [92-96]. Studies of patients in whom cysts have been resected or aspirated find that malignancy or premalignancy does not correlate with cyst size alone. These studies suggest that mucinous lesions of any size are premalignant [97,98]. However, in a series of 170 of 539 patients who underwent operative resection of pancreatic cysts, no invasive cancers were found in mucinous cysts <3 cm [90].

Nevertheless, establishing a cyst as mucinous is important because of their higher risk for the presence or future development of malignancy. Morphologic features that aid in diagnosis of a mucinous tumor include (1) the presence or absence of septae (mucinous cystic neoplasms generally are multilocular, with large cysts), (2) the position of calcification (mucinous cystic neoplasms typically

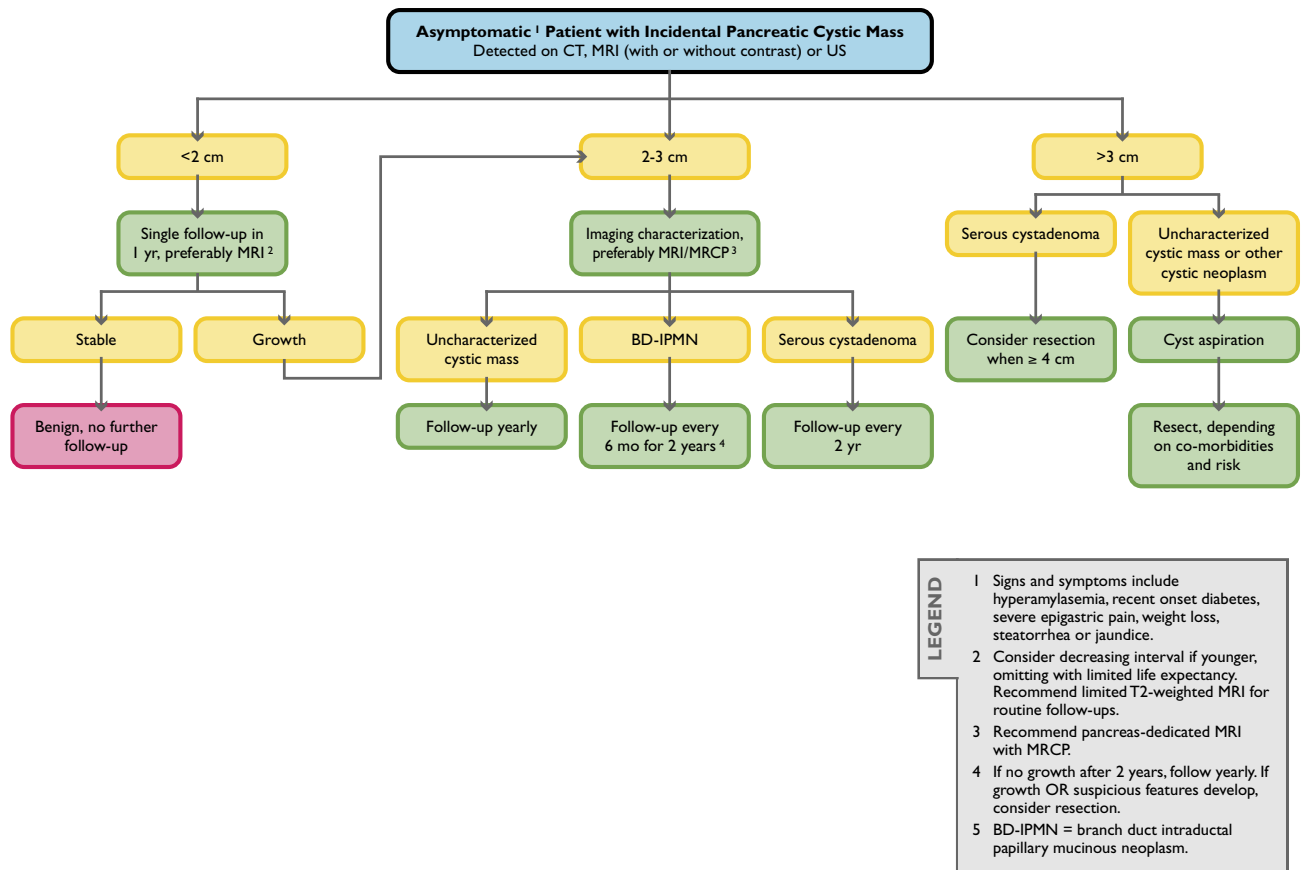


Fig 5. Flow chart for an asymptomatic patient with an incidental pancreatic cystic mass detected on CT, MRI (with or without contrast), or ultrasound (US). MRCP = MR cholangiopancreatography.

have peripheral calcification, whereas serous tumors have central calcification), (3) location within the pancreas, and (4) the presence of main pancreatic duct involvement [99-102]. Mucinous cystic tumors can be suspected when a cyst is present in the tail of the pancreas in a perimenopausal woman [84]. The presence or absence of direct communication with the main pancreatic duct must be established to distinguish a mucinous cystic tumor (with relatively high malignant potential) from a branch duct IPMN (with relatively low malignant potential). Three-dimensional imaging with either MRI or CT can address this question. Conversely, serous cystadenoma characteristically displays variably dense radial septae in a honeycombed or spongiform pattern and central calcification. The more peripheral cysts are larger than the more central cysts.

A simple but useful imaging-based classification system differentiates pancreatic cystic masses into 4 morphologic types: (1) unilocular (pseudocysts, mucinous cystic neoplasms, lymphoepithelial cysts, small IPMNs, and small serous tumors), (2) microcystic (serous cystadenomas and lymphoepithelial cysts), (3) macrocystic (mucinous cystic neoplasms, oligocystic serous tumors,

and IPMNs) and (4) cysts with solid components (solid-appearing serous tumors, solid pseudopapillary neoplasms, and cystic islet cell tumors) [103].

Implications of Imaging and Clinical Features

Most incidental cysts can be detected on routine abdominal studies. However, if a cyst needs to be characterized, it is recommended that a diagnosis of a specific cyst type not be made unless the patient undergoes a dedicated "pancreas-style" study. For multidetector CT, this would require a dual-phase contrast-enhanced acquisition in both pancreatic and portal venous phases using a narrow detector configuration. Thin-section images should be available on a workstation that can perform 3-D analysis.

Magnetic resonance imaging should be performed at 1.5 T. Phased-array torso coils enhance signal and parallel imaging increases speed and improves resolution. The study should include sequences that display in-phase and out-of-phase T1, T2 (preferably with fat suppression), and 3-D, fat-saturated, gradient-echo T1 gadolinium-enhanced sequences in pancreatic, portal, and equilibrium phases. Additionally, MR cholangiopancreatogra-

phy is necessary. Current MRI scanners have respiratory triggered 3-D sequences for MR cholangiopancreatography [104]. Secretin administration may facilitate visualization of the communication of a cyst with the main pancreatic duct [105]. By consensus, the Incidental Findings Committee suggests dedicated MRI as the imaging procedure of choice to characterize a pancreatic cyst. This reflects the superior contrast resolution of MRI, facilitating the recognition of septae, nodules, and duct communication [106].

The pretest likelihood that a given lesion in an individual patient is a malignant neoplasm is of paramount consideration when deciding on management. Controversy exists between using dedicated imaging or an attempt at aspiration of a cyst under endoscopic ultrasound guidance. Most often, this decision will be made on the basis of the size of the cyst, location within the pancreas, accessibility to the endoscopic ultrasound approach, and expertise of the endosonographer. A carcinoembryonic antigen level in the aspirate of 192 ng/mL has a high specificity for discriminating mucinous from nonmucinous cysts, demonstrating higher accuracy than cyst morphology [107]. Amylase levels of <250 U/L exclude pseudocysts. There is a high degree of overlap between the values obtained at aspiration [108]. Recent reports have documented the development of ductal adenocarcinoma in a remote site in the pancreas from an IPMN [109,110]. Many believe that the presence of a mucinous lesion is a signal of increased risk for pancreatic neoplasm anywhere within the gland.

The consensus of the Incidental Findings Committee is that if surgery is contemplated, aspiration of a pancreatic cyst ≤ 3 cm should be attempted. It is a widely held opinion, shared by this committee, that cysts <1.5 cm need not be immediately characterized, whereas it is appropriate to characterize other cysts, depending on comorbid conditions and life expectancy.

Imaging surveillance of pancreatic cystic neoplasms is controversial. However, emerging consensus suggests that selective nonoperative management in patients with incidental pancreatic cysts is appropriate [96,111,112]. In a series of 369 of 539 patients with a mean radiographic follow-up period of 24 months (range, 1-172 months), 8% developed changes that prompted resection. Malignancies were present in 38% [90]. In a retrospective case series of 79 patients with long-term follow-up, either 5 years by imaging or 8 years clinically, diagnosed with small (≤ 2 cm), simple pancreatic cysts on sonography or CT from 1985 to 1996 were reviewed. Of the 22 patients with radiologic follow-up, 59% had cysts that remained unchanged or became smaller (mean size, 8 mm; mean follow-up period, 9 years), and 41% had cysts that enlarged, from a mean of 14 mm to a mean of 26 mm (mean follow-up period, 8 years). Of the 27

patients with clinical or questionnaire follow-up (mean follow-up period, 10 years), none developed symptomatic pancreatic disease. Twenty-three percent died within 8 years without adequate radiologic follow-up, none of pancreas-related causes [113]. Another series of 90 patients with incidental cysts with a mean follow-up period of 48 months revealed malignancy in 1 patient 7 years from diagnosis [86]. The frequency of cancer in surgically resected cysts <3 cm has been reported as 19% (including symptomatic and asymptomatic patients) [114], but when only truly incidental cysts are evaluated, the frequency is reported as only 3.5% [82].

A follow-up examination must clearly establish the stability of a cyst. Therefore, patients should be advised to undergo serial imaging at facilities with protocols for dedicated pancreatic imaging. Although there is no clear consensus among pancreatic experts regarding the optimal imaging test for follow-up of pancreatic cysts, a limited MRI examination relying exclusively on T2-weighted unenhanced acquisitions has been proposed as a practical follow-up strategy [115].

Careful evaluation of the imaging findings is directed at inspecting the lesion for changes in the thickness of the wall, mural irregularities, or frank solid nodules. For branch duct IPMNs, the adjacent main pancreatic duct diameter should be recorded. The lesion should be carefully measured with slice number and series appearing in the report, and electronic calipers should be placed on the exact image used to determine the diameters. Currently, there is no consensus on defining what increment of growth is important. It is well known that the precision of manual measurement is inversely related to the lesion diameter. Thus, it may be difficult to determine if the reported growth of a small lesion is true growth or measurement error.

As of this writing, there is no universally accepted follow-up protocol. Most proposed programs are based on the Sendai criteria that arose from a consensus conference addressing the management and follow-up of mucinous pancreatic cysts. Cysts <1 cm are followed yearly, cysts between 1 and 3 cm are sent for further imaging (endoscopic ultrasound or MRI) looking for septae and mural nodules, and simple cysts are followed at 6-month intervals for 2 years and then yearly. If they grow above 3 cm or develop any worrisome features, patients are considered candidates for resection [88]. In contradistinction, a recommendation derived from reviewing 166 cysts with a mean size of 2 cm in 150 patients revealed that 89% showed no growth over 2 years. The only predictor of cyst growth was the presence of mural nodules. This study suggested no follow-up until 2 years after detection [85]. In the Incidental Findings Committee's recommendations, cysts <2 cm may be followed at 1-year intervals, and if there is no growth, follow-up ceases if the patient remains asymptomatic. A cyst that is ≥ 3 cm is considered a surgical lesion unless it is a serous cystadenoma

or if patient comorbidities preclude benefit from resection. A cyst between 2 and 3 cm may be characterized and followed semiannually if mucinous, yearly if uncharacterized, and every 2 years if it is a serous cystadenoma.

Serous cystadenoma is a benign lesion. However, studies have clearly documented that these lesions may grow. Therefore, some recommend resecting serous cystadenomas >4 cm regardless of the presence of symptoms [116], or in symptomatic patients regardless of size [90]. Solid pseudopapillary epithelial neoplasm is a low-grade malignancy that can present with cystic-appearing components. The majority are found in young women. They frequently contain peripheral calcification and variable content (most characteristically hemorrhages) within the cysts. Solid pseudopapillary epithelial neoplasm lesions should undergo resection.

Summary

The Incidental Findings Committee recommends the following for managing incidental pancreatic cysts:

1. Surgery should be considered for patients with cysts >3 cm.
 - a. If the lesion is a serous cystadenoma, surgery is deferred until the cyst is >4 cm.
 - b. Solid pseudopapillary epithelial neoplasm tumors should be resected.
 - c. Patient factors ultimately determine the appropriateness of surgical treatment.
2. Patients with simple (not containing any solid elements) cysts <3 cm can be followed.
 - a. Attempts should be made to characterize all cysts \geq 2 cm at the time of detection. Magnetic resonance imaging is the imaging procedure of choice.
 - b. Cyst aspiration is strongly advised before any surgery is undertaken in a patient with a cyst of this size.
 - c. Cysts <2 cm can be followed less frequently than those between 2 and 3 cm.
 - d. Avoid characterizing cysts <1.5 to 2 cm unless absolutely characteristic.
3. The presence of symptoms is a critical factor in deciding appropriate therapy.
 - a. The frequency of malignancy in small cysts is significantly higher in symptomatic patients.

SPECIAL CONSIDERATIONS FOR LOW-DOSE UNENHANCED CT

Because of the advent of screening CT examinations such as CT colonography and heightened concern about radiation exposure, low-dose unenhanced CT examinations of the abdomen are increasing in use. The management of incidental findings discovered either on such examinations or on conventional-dose unenhanced examinations is controversial, and there are different challenges. Low-

dose techniques will increase image noise but should not change the mean HU values to determine adrenal mass density. The following sections describe organ-specific approaches for these types of examinations that may vary from those described above.

Kidneys

The management of a renal mass detected on an unenhanced CT scan is controversial. To the best of our knowledge, no studies have addressed how best to manage non-fat-containing renal masses detected with unenhanced CT, and thus, these recommendations reflect our opinions on the basis of our experience and understanding of the prevalence and natural history of such findings. Furthermore, other than angiomyolipomas, renal masses detected incidentally on unenhanced CT scans often cannot be accurately characterized.

Our experience suggests that when a renal mass seems to be a simple cyst on an unenhanced CT scan, the chance that the mass is benign is extremely high. However, careful evaluation of the mass's features is important. To be considered a probable simple cyst on unenhanced CT, the mass should be well marginated, contain contents that are homogeneous, and water attenuation (0-20 HU), and display no septa, wall thickening, calcification (unless minimal, thin calcification within the wall), or nodularity. If any of these latter features is present, a renal mass—protocol CT or MRI would be needed to diagnose the mass with complete confidence. Sonography may be helpful, but in some cases it may not be definitive.

To our knowledge, no studies in the literature have specifically addressed the likelihood of cancers in lesions that seem to be simple cysts on unenhanced CT. Furthermore, when low-dose CT techniques are used, nonsimple (and potentially malignant) features that otherwise would be detected with standard-dose CT may not be detectable. As a theoretical example, the heterogeneity of a renal cell carcinoma may be incorrectly attributed to noise of low-dose CT and undergo no further evaluation or follow-up. Also, some simple cysts may not appear homogeneous, because of noise, so differentiating heterogeneity sometimes encountered on low-dose CT from a heterogeneous solid mass may be difficult. Hence, although the possibility of misinterpreting a renal cancer as a simple cyst exists, it is well understood that the technical factors used to perform an examination affect sensitivity and specificity.

The Incidental Findings Committee recommends the following for low-dose unenhanced CT examinations for renal masses:

1. It may be appropriate to interpret incidental renal masses as simple cysts unless suspicious features noted above are convincingly present. The argument for adopting this approach is even stronger when consid-

ering small (<3 cm) masses, particularly those <1 cm. The smaller the mass (even when solid), the more likely it is benign. Furthermore, masses <1 cm may not be able to be fully characterized, even if renal mass–protocol CT or MRI was performed. Although this represents a consensus opinion of the committee, no data are yet available to support this approach.

2. If a renal mass is small (<3 cm), homogeneous, and >70 HU, recent data suggest that the mass can be confidently diagnosed as a benign hyperattenuating cyst (Bosniak category II) [43].

Liver

The recommendations in the flowchart in Figure 3 apply to low-dose unenhanced procedures as well as standard–radiation dose enhanced examinations.

The Incidental Findings Committee recommends the following for low-dose unenhanced CT examinations for liver masses:

1. In low-risk and average-risk patients, sharply marginated, low-attenuation (<20 HU) solitary or multiple masses may typically not need further evaluation.
2. Small, solitary masses ≤ 1.5 cm that are not cystic and are discovered on unenhanced or standard-dose or low-dose scans in low-risk and average-risk patients may typically not need further evaluation.

Adrenal Glands

The low-dose unenhanced technique is less sensitive for determining the internal architecture and heterogeneity of an adrenal mass than contrast-enhanced CT with a standard radiation exposure. We are not aware of any helpful literature addressing the topic of adrenal mass characterization on low-dose unenhanced CT examinations. Therefore, these recommendations represent the consensus opinion on the basis of the clinical experience of the committee members.

The Incidental Findings Committee recommends the following for low-dose unenhanced CT examinations for adrenal masses:

1. Because attenuation should not be altered by a low-dose technique, if the mean attenuation of an adrenal mass is ≤ 10 HU on a low-dose CT examination, one may conclude that the adrenal mass is likely to be a benign adenoma.
2. If a lesion is >10 HU and 1 to 4 cm in an asymptomatic patient without cancer, 1-year follow-up CT or MRI may be considered, if no prior studies for comparison are available. Prior examinations that show stability for ≥ 1 year can eliminate the need for further workup, so every effort should be made to obtain prior CT or MRI examinations in these situations.

3. For adrenal masses >4 cm, dedicated adrenal MRI or CT should be considered to further characterize.

Pancreas

The recommendations shown in the pancreatic flowchart (Figure 5) also apply to low-dose unenhanced CT examinations. The importance of comparison with prior CT or MRI examinations cannot be overemphasized to potentially avoid further workup. Specifically, for lesions <2 cm, stability over ≥ 1 year is highly suggestive of a benign lesion and may eliminate the need for follow-up imaging.

FUTURE COMMITTEE OBJECTIVES

The Incidental Findings Committee hopes that these recommendations will become widely applied and will search for additional methods to disseminate them. The committee also expects to refine and adapt these recommendations and to develop additional guidance for other types of incidental findings. To advance the scientific evidence regarding incidental findings, the committee recommends that the concepts, terminology, and parameters discussed in this paper become the basis for future research, to help the results of such research be more easily applied within a common framework.

CONCLUSIONS

Incidental findings on imaging during daily practice have grown in number related to the rapid increase in the utilization of CT and to its improved image quality. These incidental findings potentially lead to increased risk to the patient and cost from additional procedures. Underscoring concern among physicians is the fear that failure to report incidental findings and recommend follow-up will place radiologists in jeopardy for malpractice litigation, should a lesion eventually lead to a life-threatening health problem.

This effort within the ACR, conducted by the Incidental Findings Committee, attempts to systematically describe a variety of the most common potential incidental findings on abdominal CT and provide detailed recommendations to assist practicing radiologists in making informed decisions about reporting such masses and advising their referring clinicians and patients about whether and how these should be managed. This is part of an ongoing project to develop, refine, and disseminate information about incidental findings and to collect information and support research about them.

ACKNOWLEDGMENTS

To N. Reed Dunnick, MD, who supported and helped establish the Committee within the Body Imaging Commission of the ACR and to David Kurth of the ACR staff,

who helped support and coordinate the activities that led to this manuscript.

REFERENCES

- Pickhardt PJ, Hanson ME, Vanness DJ, et al. Unsuspected extracolonic findings at screening CT colonography: clinical and economic impact. *Radiology* 2008;249:151-9.
- Bovio S, Cataldi A, Reimondo G, et al. Prevalence of adrenal incidentaloma in a contemporary computerized tomography series. *J Endocrinol Invest* 2006;29:298-302.
- Wagner SC, Morrison WB, Carrino JA, Schweitzer ME, Nothnagel H. Picture archiving and communication system: effect on reporting of incidental findings. *Radiology* 2002;225:500-5.
- Yee J, Kumar NN, Godara S, et al. Extracolonic abnormalities discovered incidentally at CT colonography in a male population. *Radiology* 2005;236:519-26.
- Incidentaloma. Available at: <http://medical-dictionary.thefreedictionary.com/Incidental+finding>. Accessed May 20, 2010.
- Parker LS. The future of incidental findings: should they be viewed as benefits? *J Law Med Ethics* 2008;36:341-51.
- Fletcher RH, Pignone M. Extracolonic findings with computed tomographic colonography: asset or liability? *Arch Intern Med* 2008;168:685-6.
- Centers for Medicare and Medicaid Services. Decision memo for screening computed tomography colonography (CTC) for colorectal cancer (CAG-00396N). Baltimore, Md: Centers for Medicare and Medicaid Services.
- Berland LL. Incidental extracolonic findings on CT colonography: the impending deluge and its implications. *J Am Coll Radiol* 2009;6:14-20.
- Hara AK, Johnson CD, MacCarty RL, Welch TJ. Incidental extracolonic findings at CT colonography. *Radiology* 2000;215:353-7.
- Hassan C, Pickhardt PJ, Laghi A, et al. Computed tomographic colonography to screen for colorectal cancer, extracolonic cancer, and aortic aneurysm: model simulation with cost-effectiveness analysis. *Arch Intern Med* 2008;168:696-705.
- Hellstrom M, Svensson MH, Lason A. Extracolonic and incidental findings on CT colonography (virtual colonoscopy). *AJR Am J Roentgenol* 2004;182:631-8.
- Xiong T, McEvoy K, Morton DG, Halligan S, Lilford RJ. Resources and costs associated with incidental extracolonic findings from CT colonography: a study in a symptomatic population. *Br J Radiol* 2006;79:948-61.
- Xiong T, Richardson M, Woodroffe R, Halligan S, Morton D, Lilford RJ. Incidental lesions found on CT colonography: their nature and frequency. *Br J Radiol* 2005;78:22-9.
- Casarella WJ. A patient's viewpoint on a current controversy. *Radiology* 2002;224:927.
- MacMahon H, Austin JH, Gamsu G, et al. Guidelines for management of small pulmonary nodules detected on CT scans: a statement from the Fleischner Society. *Radiology* 2005;237:395-400.
- Frates MC, Benson CB, Charboneau JW, et al. Management of thyroid nodules detected at US: Society of Radiologists in Ultrasound consensus conference statement. *Radiology* 2005;237:794-800.
- Grant EG, Benson CB, Moneta GL, et al. Carotid artery stenosis: gray-scale and Doppler US diagnosis—Society of Radiologists in Ultrasound Consensus Conference. *Radiology* 2003;229:340-6.
- D'Orsi CJ, Bassett LW, Berg WA, et al. Breast Imaging Reporting and Data System: ACR BI-RADS-Mammography. 4th ed. Reston, Va: American College of Radiology; 2003.
- Zalis ME, Barish MA, Choi JR, et al. CT colonography reporting and data system: a consensus proposal. *Radiology* 2005;236:3-9.
- Elstein AS. On the origins and development of evidence-based medicine and medical decision making. *Inflamm Res* 2004;53(suppl):S184-9.
- Wolf SM, Lawrenz FP, Nelson CA, et al. Managing incidental findings in human subjects research: analysis and recommendations. *J Law Med Ethics* 2008;36:219-48.
- Birnbaum BA, Bosniak MA, Megibow AJ, Lubat E, Gordon RB. Observations on the growth of renal neoplasms. *Radiology* 1990;176:695-701.
- Birnbaum BA, Hindman N, Lee J, Babb JS. Renal cyst pseudoenhancement: influence of multidetector CT reconstruction algorithm and scanner type in phantom model. *Radiology* 2007;244:767-75.
- Bosniak M. Problematic renal masses. In: RSNA categorical course in diagnostic radiology: genitourinary radiology. Oak Brook, Ill: Radiological Society of North America; 1994:183-91.
- Bosniak MA. The current radiological approach to renal cysts. *Radiology* 1986;158:1-10.
- Bosniak MA. The small (less than or equal to 3.0 cm) renal parenchymal tumor: detection, diagnosis, and controversies. *Radiology* 1991;179:307-17.
- Bosniak MA. Diagnosis and management of patients with complicated cystic lesions of the kidney. *AJR Am J Roentgenol* 1997;169:819-21.
- Bosniak MA. Should we biopsy complex cystic renal masses (Bosniak category III)? *AJR Am J Roentgenol* 2003;181:1425-6.
- Bosniak MA, Birnbaum BA, Krinsky GA, Waisman J. Small renal parenchymal neoplasms: further observations on growth. *Radiology* 1995;197:589-97.
- Bosniak MA, Megibow AJ, Hulnick DH, Horii S, Raghavendra BN. CT diagnosis of renal angiomyolipoma: the importance of detecting small amounts of fat. *AJR Am J Roentgenol* 1988;151:497-501.
- Bosniak MA, Rofsky NM. Problems in the detection and characterization of small renal masses. *Radiology* 1996;198:638-41.
- Curry NS, Cochran ST, Bissada NK. Cystic renal masses: accurate Bosniak classification requires adequate renal CT. *AJR Am J Roentgenol* 2000;175:339-42.
- Harisinghani MG, Maher MM, Gervais DA, et al. Incidence of malignancy in complex cystic renal masses (Bosniak category III): should imaging-guided biopsy precede surgery? *AJR Am J Roentgenol* 2003;180:755-8.
- Hartman DS, Weatherby E III, Laskin WB, Brody JM, Corse W, Baluch JD. Cystic renal cell carcinoma: CT findings simulating a benign hyperdense cyst. *AJR Am J Roentgenol* 1992;159:1235-7.
- Israel GM, Bosniak MA. Follow-up CT of moderately complex cystic lesions of the kidney (Bosniak category IIF). *AJR Am J Roentgenol* 2003;181:627-33.
- Israel GM, Bosniak MA. Calcification in cystic renal masses: is it important in diagnosis? *Radiology* 2003;226:47-52.
- Israel GM, Bosniak MA. How I do it: evaluating renal masses. *Radiology* 2005;236:441-50.
- Israel GM, Hindman N, Bosniak MA. Evaluation of cystic renal masses: comparison of CT and MR imaging by using the Bosniak classification system. *Radiology* 2004;231:365-71.
- Israel GM, Hindman N, Hecht E, Krinsky G. The use of opposed-phase chemical shift MRI in the diagnosis of renal angiomyolipomas. *AJR Am J Roentgenol* 2005;184:1868-72.
- Jinzaki M, McTavish JD, Zou KH, Judy PF, Silverman SG. Evaluation of small (≤ 3 cm) renal masses with MDCT: benefits of thin overlapping reconstructions. *AJR Am J Roentgenol* 2004;183:223-8.

42. Jinzaki M, Tanimoto A, Narimatsu Y, et al. Angiomyolipoma: imaging findings in lesions with minimal fat. *Radiology* 1997;205:497-502.
43. Jonisch AI, Rubinowitz AN, Mutalik PG, Israel GM. Can high-attenuation renal cysts be differentiated from renal cell carcinoma at unenhanced CT? *Radiology* 2007;243:445-50.
44. Kim JK, Park SY, Shon JH, Cho KS. Angiomyolipoma with minimal fat: differentiation from renal cell carcinoma at biphasic helical CT. *Radiology* 2004;230:677-84.
45. Silverman S, Gan, YU, Mortele, KJ, Tuncali, K, Cibas, ES. Renal mass biopsy in the new millennium: an important diagnostic procedure. In: *RSNA categorical course in diagnostic radiology: genitourinary radiology*. Chicago, Ill: Radiological Society of North America; 2006:219-36.
46. Silverman SG, Gan YU, Mortele KJ, Tuncali K, Cibas ES. Renal masses in the adult patient: the role of percutaneous biopsy. *Radiology* 2006;240:6-22.
47. Silverman SG, Mortele KJ, Tuncali K, Jinzaki M, Cibas ES. Hyperattenuating renal masses: etiologies, pathogenesis, and imaging evaluation. *Radiographics* 2007;27:1131-43.
48. Silverman SG, Israel GM, Herts BR, Richie JP. Management of the incidental renal mass. *Radiology* 2008;249:16-31.
49. Campbell SC, Novick AC, Beldegrun A, et al. Guideline for management of the clinical T1 renal mass. *J Urol* 2009;182:1271-9.
50. American Urological Association. Guideline for management of the clinical stage I renal mass. Available at: <http://www.auanet.org/content/media/renalmass09.pdf?CFID=2980781&CFTOKEN=53338937&jsessionid=84305943038372e237f85a47377557304155>. Accessed May 15, 2010.
51. Kassouf W, Aprikian AG, Laplante M, Tanguay S. Natural history of renal masses followed expectantly. *J Urol* 2004;171:111-3.
52. Kunkle DA, Crispen PL, Chen DY, Greenberg RE, Uzzo RG. Enhancing renal masses with zero net growth during active surveillance. *J Urol* 2007;177:849-53.
53. Thompson RH, Kurta JM, Kaag M, et al. Tumor size is associated with malignant potential in renal cell carcinoma cases. *J Urol* 2009;181:2033-6.
54. Nguyen MM, Gill IS. Effect of renal cancer size on the prevalence of metastasis at diagnosis and mortality. *J Urol* 2009;181:1020-7.
55. Frank I, Blute ML, Cheville JC, Lohse CM, Weaver AL, Zincke H. Solid renal tumors: an analysis of pathological features related to tumor size. *J Urol* 2003;170:2217-20.
56. Washington K. Masses of the liver. In: *Odze R, Goldblum JR, eds. Surgical pathology of the GI tract, liver, biliary tract and pancreas*. 2nd ed. New York: Elsevier; 2009:657-789.
57. Padia SA, Baker ME, Schaeffer CJ, et al. Safety and efficacy of sonographic-guided random real-time core needle biopsy of the liver. *J Clin Ultrasound* 2009;37:138-43.
58. Appelbaum L, Kane RA, Kruskal JB, Romero J, Sosna J. Focal hepatic lesions: US-guided biopsy-lessons from review of cytologic and pathological examination results. *Radiology* 2009;250:453-8.
59. Whitmire LF, Galambos JT, Phillips VM, et al. Imaging guided percutaneous hepatic biopsy: diagnostic accuracy and safety. *J Clin Gastroenterol* 1985;7:511-5.
60. NIH state-of-the-science statement on management of the clinically inapparent adrenal mass ("incidentaloma"). *NIH Consens State Sci Statements* 2002;19:1-25.
61. Choyke PL. ACR Appropriateness Criteria[®] on incidentally discovered adrenal mass. *J Am Coll Radiol* 2006;3:498-504.
62. Grumbach MM, Biller BM, Braunstein GD, et al. Management of the clinically inapparent adrenal mass ("incidentaloma"). *Ann Intern Med* 2003;138:424-9.
63. Young WF Jr. Clinical practice. The incidentally discovered adrenal mass. *N Engl J Med* 2007;356:601-10.
64. Mansmann G, Lau J, Balk E, Rothberg M, Miyachi Y, Bornstein SR. The clinically inapparent adrenal mass: update in diagnosis and management. *Endocr Rev* 2004;25:309-40.
65. Song JH, Chaudhry FS, Mayo-Smith WW. The incidental adrenal mass on CT: prevalence of adrenal disease in 1,049 consecutive adrenal masses in patients with no known malignancy. *AJR Am J Roentgenol* 2008;190:1163-8.
66. Boland GW, Blake MA, Hahn PF, Mayo-Smith WW. Incidental adrenal lesions: principles, techniques, and algorithms for imaging characterization. *Radiology* 2008;249:756-75.
67. Boland GW, Lee MJ, Gazelle GS, Halpern EF, McNicholas MM, Mueller PR. Characterization of adrenal masses using unenhanced CT: an analysis of the CT literature. *AJR Am J Roentgenol* 1998;171:201-4.
68. Fujiyoshi F, Nakajo M, Fukukura Y, Tsuchimochi S. Characterization of adrenal tumors by chemical shift fast low-angle shot MR imaging: comparison of four methods of quantitative evaluation. *AJR Am J Roentgenol* 2003;180:1649-57.
69. Israel GM, Korobkin M, Wang C, Hecht EN, Krinsky GA. Comparison of unenhanced CT and chemical shift MRI in evaluating lipid-rich adrenal adenomas. *AJR Am J Roentgenol* 2004;183:215-9.
70. Korobkin M, Giordano TJ, Brodeur FJ, et al. Adrenal adenomas: relationship between histologic lipid and CT and MR findings. *Radiology* 1996;200:743-7.
71. Lee MJ, Hahn PF, Papanicolaou N, et al. Benign and malignant adrenal masses: CT distinction with attenuation coefficients, size, and observer analysis. *Radiology* 1991;179:415-8.
72. Mayo-Smith WW, Lee MJ, McNicholas MM, Hahn PF, Boland GW, Saini S. Characterization of adrenal masses (<5 cm) by use of chemical shift MR imaging: observer performance versus quantitative measures. *AJR Am J Roentgenol* 1995;165:91-5.
73. Caoili EM, Korobkin M, Francis IR, et al. Adrenal masses: characterization with combined unenhanced and delayed enhanced CT. *Radiology* 2002;222:629-33.
74. Korobkin M, Brodeur FJ, Francis IR, Quint LE, Dunnick NR, Londy F. CT time-attenuation washout curves of adrenal adenomas and nonadenomas. *AJR Am J Roentgenol* 1998;170:747-52.
75. Pena CS, Boland GW, Hahn PF, Lee MJ, Mueller PR. Characterization of indeterminate (lipid-poor) adrenal masses: use of washout characteristics at contrast-enhanced CT. *Radiology* 2000;217:798-802.
76. Boland GW, Blake MA, Holalkere NS, Hahn PF. PET/CT for the characterization of adrenal masses in patients with cancer: qualitative versus quantitative accuracy in 150 consecutive patients. *AJR Am J Roentgenol* 2009;192:956-62.
77. Paulsen SD, Nghiem HV, Korobkin M, Caoili EM, Higgins EJ. Changing role of imaging-guided percutaneous biopsy of adrenal masses: evaluation of 50 adrenal biopsies. *AJR Am J Roentgenol* 2004;182:1033-7.
78. Silverman SG, Mueller PR, Pinkney LP, Koenker RM, Seltzer SE. Predictive value of image-guided adrenal biopsy: analysis of results of 101 biopsies. *Radiology* 1993;187:715-8.
79. Spinelli KS, Fromwiller TE, Daniel RA, et al. Cystic pancreatic neoplasms: observe or operate. *Ann Surg* 2004;239:651-9.
80. Laffan TA, Horton KM, Klein AP, et al. Prevalence of unsuspected pancreatic cysts on MDCT. *AJR Am J Roentgenol* 2008;191:802-7.

81. Zhang XM, Mitchell DG, Dohke M, Holland GA, Parker L. Pancreatic cysts: depiction on single-shot fast spin-echo MR images. *Radiology* 2002;223:547-53.
82. Fernández-del Castillo C, Targarona J, Thayer SP, Rattner DW, Brugge WR, Warshaw AL. Incidental pancreatic cysts: clinicopathologic characteristics and comparison with symptomatic patients. *Arch Surg* 2003;138:427-34.
83. Levy P, Jouannaud V, O'Toole D, et al. Natural history of intraductal papillary mucinous tumors of the pancreas: actuarial risk of malignancy. *Clin Gastroenterol Hepatol* 2006;4:460-8.
84. Adsay NV. Cystic neoplasia of the pancreas: pathology and biology. *J Gastrointest Surg* 2008;12:401-4.
85. Das A, Wells CD, Nguyen CC. Incidental cystic neoplasms of pancreas: what is the optimal interval of imaging surveillance? *Am J Gastroenterol* 2008;103:1657-62.
86. Lahav M, Maor Y, Avidan B, Novis B, Bar-Meir S. Nonsurgical management of asymptomatic incidental pancreatic cysts. *Clin Gastroenterol Hepatol* 2007;5:813-7.
87. Sahani DV, Saokar A, Hahn PF, Brugge WR, Fernández-Del Castillo C. Pancreatic cysts 3 cm or smaller: how aggressive should treatment be? *Radiology* 2006;238:912-9.
88. Tanaka M, Chari S, Adsay V, et al. International consensus guidelines for management of intraductal papillary mucinous neoplasms and mucinous cystic neoplasms of the pancreas. *Pancreatol* 2006;6:17-32.
89. Walsh RM, Vogt DP, Henderson JM, et al. Natural history of indeterminate pancreatic cysts. *Surgery* 2005;138:665-71.
90. Allen PJ, D'Angelica M, Gonen M, et al. A selective approach to the resection of cystic lesions of the pancreas: results from 539 consecutive patients. *Ann Surg* 2006;244:572-82.
91. Gomez D, Rahman SH, Wong LF, Verbeke CS, Menon KV. Predictors of malignant potential of cystic lesions of the pancreas. *Eur J Surg Oncol* 2008;34:876-82.
92. Lee SH, Shin CM, Park JK, et al. Outcomes of cystic lesions in the pancreas after extended follow-up. *Dig Dis Sci* 2007;52:2653-9.
93. Salvia R, Crippa S, Falconi M, et al. Branch-duct intraductal papillary mucinous neoplasms of the pancreas: to operate or not to operate? *Gut* 2007;56:1086-90.
94. Bassi C, Crippa S, Salvia R. Intraductal papillary mucinous neoplasms (IPMNs): is it time to (sometimes) spare the knife? *Gut* 2008;57:287-9.
95. Javle M, Shah P, Yu J, et al. Cystic pancreatic tumors (CPT): predictors of malignant behavior. *J Surg Oncol* 2007;95:221-8.
96. Brounts LR, Lehmann RK, Causey MW, Sebesta JA, Brown TA. Natural course and outcome of cystic lesions in the pancreas. *Am J Surg* 2009;197:619-23.
97. Goh BK, Tan YM, Cheow PC, et al. Cystic lesions of the pancreas: an appraisal of an aggressive resectional policy adopted at a single institution during 15 years. *Am J Surg* 2006;192:148-54.
98. Walsh RM, Vogt DP, Henderson JM, et al. Management of suspected pancreatic cystic neoplasms based on cyst size. *Surgery* 2008;144:677-85.
99. Procacci C, Graziani R, Bicego E, et al. Serous cystadenoma of the pancreas: report of 30 cases with emphasis on the imaging findings. *J Comput Assist Tomogr* 1997;21:373-82.
100. Procacci C, Biasiutti C, Carbognin G, et al. Characterization of cystic tumors of the pancreas: CT accuracy. *J Comput Assist Tomogr* 1999;23:906-12.
101. Rautou PE, Levy P, Vullierme MP, et al. Morphologic changes in branch duct intraductal papillary mucinous neoplasms of the pancreas: a midterm follow-up study. *Clin Gastroenterol Hepatol* 2008;6:807-14.
102. Procacci C, Carbognin G, Accordini S, et al. CT features of malignant mucinous cystic tumors of the pancreas. *Eur Radiol* 2001;11:1626-30.
103. Sahani DV, Kadavigere R, Saokar A, Fernández-del Castillo C, Brugge WR, Hahn PF. Cystic pancreatic lesions: a simple imaging-based classification system for guiding management. *Radiographics* 2005;25:1471-84.
104. Sodickson A, Mortelet KJ, Barish MA, Zou KH, Thibodeau S, Tempany CM. Three-dimensional fast-recovery fast spin-echo MRCP: comparison with two-dimensional single-shot fast spin-echo techniques. *Radiology* 2006;238:549-59.
105. Carbognin G, Pinali L, Girardi V, Casarin A, Mansueto G, Mucelli RP. Collateral branches IPMTs: secretin-enhanced MRCP. *Abdom Imaging* 2007;32:374-80.
106. Waters JA, Schmidt CM, Pinchot JW, et al. CT vs MRCP: optimal classification of IPMN type and extent. *J Gastrointest Surg* 2008;12:101-9.
107. Brugge WR, Lewandrowski K, Lee-Lewandrowski E, et al. Diagnosis of pancreatic cystic neoplasms: a report of the cooperative pancreatic cyst study. *Gastroenterology* 2004;126:1330-6.
108. van der Waaij LA, van Dullemen HM, Porte RJ. Cyst fluid analysis in the differential diagnosis of pancreatic cystic lesions: a pooled analysis. *Gastrointest Endosc* 2005;62:383-9.
109. Tada M, Kawabe T, Arizumi M, et al. Pancreatic cancer in patients with pancreatic cystic lesions: a prospective study in 197 patients. *Clin Gastroenterol Hepatol* 2006;4:1265-70.
110. Uehara H, Nakaizumi A, Ishikawa O, et al. Development of ductal carcinoma of the pancreas during follow-up of branch duct intraductal papillary mucinous neoplasm of the pancreas. *Gut* 2008;57:1561-5.
111. Edirimanne S, Connor SJ. Incidental pancreatic cystic lesions. *World J Surg* 2008;32:2028-37.
112. Bassi C, Sarr MG, Lillemoe KD, Reber HA. Natural history of intraductal papillary mucinous neoplasms (IPMN): current evidence and implications for management. *J Gastrointest Surg* 2008;12:645-50.
113. Handrich SJ, Hough DM, Fletcher JG, Sarr MG. The natural history of the incidentally discovered small simple pancreatic cyst: long-term follow-up and clinical implications. *AJR Am J Roentgenol* 2005;184:20-3.
114. Lee CJ, Scheiman J, Anderson MA, et al. Risk of malignancy in resected cystic tumors of the pancreas < or = 3 cm in size: is it safe to observe asymptomatic patients? A multi-institutional report. *J Gastrointest Surg* 2008;12:234-42.
115. Macari M, Lee T, Kim S, et al. Is gadolinium necessary for MRI follow-up evaluation of cystic lesions in the pancreas? Preliminary results. *AJR Am J Roentgenol* 2009;192:159-64.
116. Tseng JF, Warshaw AL, Sahani DV, Lauwers GY, Rattner DW, Fernández-del Castillo C. Serous cystadenoma of the pancreas: tumor growth rates and recommendations for treatment. *Ann Surg* 2005;242:413-21.

APPENDIX

Committee Members

Incidental Findings Committee: Lincoln L. Berland, MD, chair.

Kidney Subcommittee: Stuart G. Silverman, MD, chair, Joel F. Platt, MD, Brian R. Herts, MD, and Gary M. Israel, MD.

Liver Subcommittee: Richard M. Gore, MD, chair, Michael P. Federle, MD, Mark E. Baker, MD, and W. Dennis Foley, MD.

Adrenal Gland Subcommittee: William W. Mayo-Smith, MD, chair, Joel F. Platt, MD, Brian R. Herts, MD, Glenn A. Krinsky, MD, and Isaac R. Francis, MD.

Pancreas Subcommittee: Alec J. Megibow, MD, MPH, chair, Richard M. Gore, MD, Mark E. Baker, MD, and Andrew J. Taylor, MD.

Lexicon Subcommittee: Lincoln L. Berland, MD, chair, William P. Shuman, MD, Stuart G. Silverman, MD, and Alec J. Megibow, MD, MPH.

ACR Colon Colonography Committee: Judy Yee, MD, chair.

Ex Officio: James A. Brink, MD, chair, Body Imaging Commission.



To access the article and take the exam, log in to www.acr.org and click on the CME icon located next to the *JACR* cover. Follow the instructions and answer 3 questions to complete the requirement for CME. Claim the credit and print your CME certificate online. *Note: CME for ACR members is free, however you will need to click on the "Buy Now" button and proceed through the shopping cart process in order to receive the credit.*

Accreditation Statement

The American Roentgen Ray Society is accredited by the Accreditation Council on Continuing Medical Education to provide continuing medical education for physicians.

Designation Statement

The American Roentgen Ray Society designates this educational activity for a maximum of 1 *AMA PRA Category 1 Credit(S)*TM. Physicians should only claim credit commensurate with the extent of their participation in the activity.

The American Medical Association has determined that physicians not licensed in the U.S. who participate in this CME activity are eligible for *AMA PRA Category 1 Credit(S)*TM.

The American Roentgen Ray Society is a strategic partner of the American College of Radiology.

Faculty Disclosure Statements

The faculty members listed below have indicated that they have no relevant financial relationships or potential conflicts of interest related to the material presented, and they do not discuss the use of a medical device or pharmaceutical that is classified by the FDA as investigational for the intended use, or that is "off-label," e.g., a use not described on the product's label.

- Richard M. Gore, MD
- William W. Mayo-Smith, MD
- Alec J. Megibow, MD, MPH
- James A. Brink, MD
- Michael P. Federle, MD
- Issac R. Francis, MD
- Brian R. Herts, MD
- Gary M. Israel, MD
- Glenn Krinsky, MD
- Joel F. Platt, MD
- Andrew J. Taylor, MD

The faculty members listed below have disclosed the following financial relationship and there are no conflicts of interest related to their material, and they do not discuss the use of a medical device or pharmaceutical that is classified by the FDA as investigational for the intended use, or that is "off-label," e.g., a use not described in the product's label.

- Lincoln L. Berland, MD - Consultant, Nuance, Inc.
- Stuart G. Silverman, MD - Book Royalties, Lippincott, Williams, & Wilkins
- Judy Yee, MD - Research Grant, GE Healthcare
- Mark E. Baker, MD - Informal Consultant on Volumen, Bracco; Research Agreement, Siemens's Medical Systems
- W. Dennis Foley, MD - Medical Advisory Board Honorarium, GE Healthcare
- William P. Shuman, MD - Clinical Research Grant, GE Healthcare